

Case Report

Clinically Mild form of Joubert Syndrome-related Disorder in a 7-year-old Female : A case report

George Imataka, Yoshiyuki Watabe, Osamu Arisaka

Department of Pediatrics, Dokkyo Medical University School of Medicine

SUMMARY

Joubert syndrome-related disorders (JSRD) is a very rare syndrome observed with agenesis of the vermis, episodic hyperpnea, abnormal eye movements, and cerebellar ataxia and mental retardation. There have been many reports on the image-based diagnosis using MRI/CT, but not many clinical reports on the intelligence of subjects with JSRD. We herein report a clinically mild form of JSRD in a 7-year-old female. The patient did not have any clinical abnormalities in the neonatal period.

She initially visited the neurology outpatient department at 6 months of age because her neck was still unstable. A brain MRI was conducted to assess symptoms of abnormal eye movements and body trunk cerebellar ataxia, and she was diagnosed with JSRD based on the observation of agenesis of the vermis and characteristic molar tooth signs. Regarding her motor development, she was able to hold her head up at 7 months of age, and was able to sit up at 1 year and 2 months old. She underwent rehabilitation, and a wide base cerebellar gait was observed when she was 5 years old. In addition, at 5 years of age, she could intermittently speak two-word sentences, draw pictures with an understanding of color, and was able to engage in actions such as throwing a ball. At 6 years of age, her conversation became better. She entered elementary school at 7 years of age, was able to go up and down stairs, read words, do single-digit addition, and write many Chinese characters with a pencil. The intellectual dysfunction of subjects with JSRD is generally moderate to severe. Thus, this case was diagnosed to be a clinically mild form of JSRD, because the patient exhibited limited effects on her intelligence.

Key Words : cerebellar hypoplasia, molar tooth malformation, Joubert syndrome-related disorders

INTRODUCTION

In 1969, Joubert reported five cases where the patients had episodic hyperpnea, abnormal eye movements, ataxia, and mental retardation¹⁾. Patients with Joubert syndrome have characteristic imaging findings with impairment/hypoplasia of the cerebellar vermis and molar tooth signs (the mid pons transition looks like molars on horizontal MRI/CT slicing due to the

superior cerebellar peduncle). In clinical terms, abnormal breathing with repeated tachypnea and apnea are generally exhibited from the neonatal period, and ocular motor apraxia, ataxia, mental retardation, as well as autism were observed as the patients aged^{2~4)}. A few causative genes have been identified, for example, *AH11* (*Joubertin*), *NPHP1* (*nephrocystin*), *NPHP6*, *CEP290*, and *TMEM67* (*MSK3*), the hereditary form of which is due to autosomal recessive inheritance, and these were classified as Joubert syndrome-related disorder (JSRD) nosologically^{5~7)}. The impairment of the intellectual development of patients with JSRD is generally moderate to severe. We herein report the clinical course of a clinically mild case with JSRD.

Received March 7, 2012 ; accepted May 24, 2012

Reprint requests to : George Imataka MD, PhD

880 Kitakobayashi, Mibu, Shimotsuga, Tochigi
321-0293 Japan

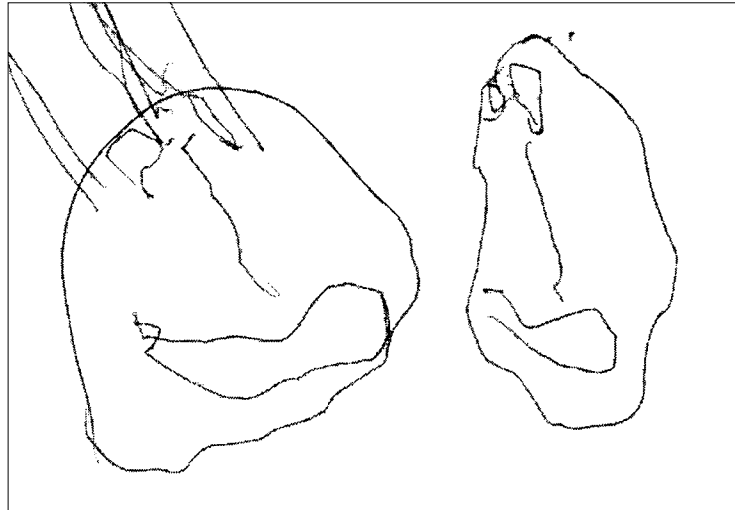

Figure 1 A drawing made by the patient at 5 years of age. The mother is drawn on the left side, while the doctor is drawn on the right side.

CASE REPORT

A female infant weighing 3,790 g and that was 50.5 cm in height at 40 weeks 4 days gestation was born by natural delivery. The mother was multiparous. She has no family history of any diseases. There were no external malformations such as polydactyly, etc. Phototherapy was conducted 5 days after birth for neonatal jaundice. The results of health examinations at 1 and 3 months were normal, and the infant's weight increase was also good. However, neck instability was observed at 5 months after birth. A brain MRI was conducted, and impairment of the cerebellar vermis, an elongated front superior cerebellar peduncle, and interpeduncular cistern of the deep anterior midbrain, that is to say, molar tooth signs, were observed. A diagnosis was made of JSRD-associated disease. The G-band chromosome banding was a normal karyotype. A genetic analysis was not performed. Differentiation of the associated diseases is required for JSRD, and therefore, a careful examination of the entire body was conducted. Findings of congenital amaurosis and retinal dystrophy were not observed. The patient's visual evoked potential and eye retinograms both showed normal responses. There were no abnormalities in the patient's mouth. Facial blepharoptosis was not noted. With regard to subsequent motor development, the neck became stable at 7 months from birth, and the infant was able to sit at 1 year and 2 months old. The infant spoke words

such as "mom," "dad," etc., at 2 years of age. Rehabilitation was conducted, and actions such as throwing a ball were possible from a walker at 2 years old, and with an ankle-foot orthosis at 5 years old, which were accompanied by the observation of a wide base cerebellar gait and cerebellar ataxia. This patient intermittently spoke two-word sentences and drew pictures (Figure 1). A molar tooth sign was observed upon brain CT (Figure 2A/2B). The patient's conversation became smooth at 6 years old. She was able to enter elementary school at 7 years old, was able to go up and down stairs, read words, and was able to do single-digit addition, moreover, she could write many Chinese characters (Figure 3). A tic was observed when she practiced words due to psychological stress. This case was diagnosed as an intellectually mild form of JSRD.

DISCUSSION

A patient cannot be diagnosed with Joubert syndrome based on a molar tooth sign alone. There are other classifications of diseases observed with abnormalities of the brain stem, cerebellum and with the molar tooth sign that need to be included in the differential diagnosis^{8~13)}. These include Arima syndrome (Dekaban-Arima syndrome), Senior-Loken syndrome, COACH syndrome (cerebellar vermis hypoplasia/aplasia, oligophrenia, congenital nonprogressive ataxia, coloboma, hepatic fibrosis), Varadi-Papp Syndrome

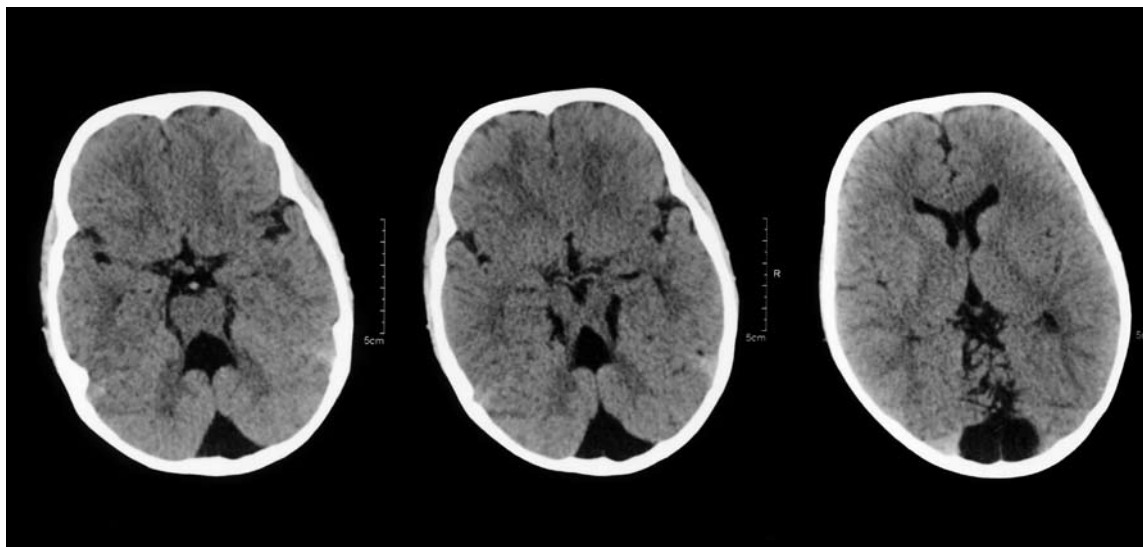


Figure 2 A/B A Brain CT scan performed at 5 years of age. An axial image at the level of the midbrain shows the enlarged superior cerebellar peduncles and the absence of the vermis. This has been called the “molar tooth sign.”




Figure 3 At 7 years of her age, the patient was able to write many Chinese characters using a pencil.

(orofacioidigital syndrome type IV), etc. As indicated in Table 1, other complications were ruled out in this case, and a clinical diagnosis of JSRD was made. In this case, the patient was able to speak, and she was able to walk up and down stairs, although she had a wide base cerebellar gait. Because of her progress and abilities, the patient was diagnosed with a relatively mild case of JSRD. The patient could also not only perform simple addition and draw pictures, but after she entered elementary school at 7 years of age, could read words, and was able to write many Chinese characters. Generally, the intellectual dysfunction of subjects with

JSRD is moderate to severe. Thus, our patient was diagnosed with an intellectually mild form of JSRD.

There have been many reports on causative genes, such as *AHI1* (Joubertin), *NPHP1* (*nephrocystin*), *NPHP6*, *CEP290*, *TMEM67* (*MSK3*) and/or MRI/CT results and reports on the ways to differentiate similar symptoms and complications regarding JSRD ; however, there are not many reports regarding the intellectual clinical manifestations associated with JSRD. Therefore, reports on relatively intellectually mild cases of JSRD, such as this report, are clinically very important. This case was concluded to be due to auto-

Table 1 Joubert syndrome related disorders associated with the molar tooth malformation

	Joubert syndrome	Arima syndrome	Senior-Loken syndrome	COACH syndrome	Varadi-Papp syndrome
retinopathy	–	+	+	–	–
tumor of the tongue	–	–	–	–	+
hepatic fibrosis	–	+/-	–	+	–
nephronophthisis	–	+	+	–	–

somal recessive inheritance, and genetic counseling regarding their next child is planned for the family. In the long term, a case in which renal insufficiency advanced after the age of 20 was reported in congenital ocular motor apraxia exhibiting similar findings as JSRD¹⁴). Therefore, periodic examinations of the kidneys will be performed in the future.

Acknowledgement We would like to thank Professor Ohno Kousaku (Department of Child Neurology, Institute of Neurological Sciences), and Professor Hideo Yamanouchi (Department of Pediatrics, Saitama Medical University), who gave us valuable suggestions regarding the clinical diagnosis of this case.

REFERENCES

- 1) Joubert M, Eisenring JJ, Robb JP, Andermann F : Familial agenesis of the cerebellar vermis. A syndrome of episodic hyperpnea, abnormal eye movements, ataxia, and mental retardation. *Neurology* **19** : 813–825, 1969.
- 2) King MD, Dudgeon J, Stephenson JBP : Joubert's syndrome with retinal dysplasia : neonatal tachypnea as the clue to a genetic brain-eye malformation. *Arch Dis Child* **59** : 709–718, 1984.
- 3) Kendall B, Kingsley D, Lambert SR, Taylor D, Finn P : Joubert syndrome : a clinical-radiological study. *Neuroradiology* **31** : 502–506, 1990.
- 4) Boltshauser E, Herdon M, Dumermuth G, Isler W : Joubert syndrome : clinical and polygraphic observations in a further case. *Neuropediatrics* **12** : 181–191, 1981.
- 5) Valente EM, Brancati F, Silhavy JL, et al : AHI1 gene mutations cause specific forms of Joubert syndrome related disorders. *Ann Neurol* **59** : 527–534, 2006.
- 6) Otto EA, Tory K, Attanasio M, et al : Hypomorphic mutations in meckelin (MKS3/TMEM67) cause nephronophthisis with liver fibrosis (NPHP11). *J Med Genet* **46** : 663–670, 2009.
- 7) Tory K, Lacoste T, Burglen L, et al : High NPHP1 and NPHP6 mutation rate in patients with Joubert syndrome and nephronophthisis : potential epistatic effect of NPHP6 and AHI1 mutations in patients with NPHP1 mutations. *J Am Soc Nephrol* **18** : 1566–1575, 2007.
- 8) Sattar S, Gleeson JG : The ciliopathies in neuronal development : a clinical approach to investigation of Joubert syndrome and Joubert syndrome-related disorders. *Dev Med Child Neurol* **53** : 793–798, 2011.
- 9) Kumada S, Hayashi M, Arima K, et al : Retinal disease in Arima syndrome is nephronophthisis as in other Joubert-related Cerebello-oculo-retinal syndromes. *Am J Med Genet A* **131** : 71–76, 2004.
- 10) Stone EM, Cideciyan AV, Aleman TS, et al : Variations in NPHP5 in patients with nonsyndromic leber congenital amaurosis and Senior-Loken syndrome. *Arch Ophthalmol* **129** : 81–87, 2011.
- 11) Weiland MD, Nowicki MJ, Jones JK, Giles HW : COACH syndrome : an unusual cause of neonatal cholestasis. *J Pediatr* **158** : 858–858.e.1, 2011.
- 12) Chodirker BN, Shah NS, Bunge MK, Reed MH : Another case of Varadi-Papp Syndrome with molar tooth sign. *Am J Med Genet A* **136A** : 416–417, 2005.
- 13) Stephan MJ, Brooks KL, Moore DC, et al : Hypothalamic hamartoma in oral-facial-digital syndrome type IV (Varadi syndrome). *Am J Med Genet* **51** : 131–136, 1994.
- 14) Kondo A, Saito Y, Floricel F, Maegaki Y, Ohno K : Congenital ocular motor apraxia : clinical and neuro-radiological findings, and long-term intellectual prognosis. *Brain Dev* **29** : 431–438, 2007.