

Originals

## Clinical features and subdural lesions in childhood onset *Haemophilus influenzae* meningitis

George Imataka<sup>1</sup>, Atsushi Yoshida<sup>2</sup>, Keiko Tsukada<sup>1</sup>, Satomi Koyama<sup>1</sup>,  
Naoto Shimura<sup>1</sup>, Keitaro Fukushima<sup>1</sup>, Osamu Arisaka<sup>1</sup>

*Department of Pediatrics<sup>1</sup> and Clinical Laboratory Medicine<sup>2</sup>, Dokkyo Medical University School of Medicine*

### SUMMARY

It becomes difficult to treat the onset of childhood *Haemophilus influenzae* type b (Hib) meningitis due to the appearance of  $\beta$ -lactamase negative ampicillin resistance (BLNAR). We investigated the clinical features of Hib meningitis with subdural lesions. From January 2000 to December 2006, we experienced 8 patients with Hib meningitis. All patients were not inoculated with Hib vaccine. Five of them were onset under 1 year old. Rapid latex diagnoses were made in 5 patients, among whom 4 patients showed Hib positive. The genotypes were determined in 4 patients with BLNAR. Combined with cefotaxime sodium (CTX) and ampicillin (ABPC) were used in 3 patients for the initial antibiotics, panipenem/betamipron (PAPM/BP) in 2, meropenem hydrate (MEPM) in 1, MEPM + ceftriaxone sodium (CTRX) in 1, and concomitant use of dexamethasone in 7 patients. MRI showed subdural hygroma in 4 patients and subdural abscess in 4 patients. Subdural lesions appeared on Day 1 to Day 18 from the onset. Three patients with subdural abscess have performed subdural taps, and 2 of them with difficulties after subdural taps were necessary to do oral administration of chloramphenicol (CP).

In our report, all of the patients developed subdural lesions. The development of subdural lesions cannot be avoided with only the conventional antibiotics and dexamethasone therapy. Our cases suggested earlier subdural taps with oral administration of CP might be to improve both the general condition and control the subdural lesions with Hib meningitis. Moreover, we should pay attention to the preventive vaccination of Hib.

**Key Words** : *Haemophilus Influenzae*, subdural hygroma, subdural hematoma, vaccine, magnetic resonance imaging, single photon emission computed tomography

### INTRODUCTION

Bacterial meningitis caused by infantile *Haemophilus influenzae* type b (Hib) is a bacterial infectious disease with a poor prognosis wherein death occurs in about over 5% of all patients<sup>1~7)</sup> and lingering after effects

such as epilepsy and auditory damage with hearing loss are evident in approximately 25% of all patients<sup>8,9)</sup>, even at present, after the advancement of treatment via antibiotics. Furthermore, in recent years, with the increase in the use of antibiotics in children, Hib has rapidly become drug resistant  $\beta$ -lactamase negative ampicillin resistance (BLNAR), and Hib infections associated with meningitis, septicemia, acute epiglottitis, etc., tend to be increasingly intractable<sup>10,11)</sup>.

On such the situation, in 1998, the World Health Organization (WHO) released a statement to promote

Received June 28, 2010 ; accepted October 27, 2010

Reprint requests to : George Imataka MD

880, Kitakobayashi, Mibu, Shimotsuga,  
Tochigi 321-0293 Japan

regular vaccination with a Hib vaccine in infants, and regular vaccinations were subsequently introduced in more than 100 countries, including developing countries throughout the world<sup>12-16</sup>. By the enforcement of the regular vaccination of Hib on the international scale by WHO, the frequency of meningitis due to Hib has rapidly decreased, so it is believed that it is a rare disease on a global scale.

On the other hand, no Hib vaccine had yet been approved in Japan<sup>11</sup>. Therefore meningitis by Hib still developed in more than 600 patients annually in Japan. In January 2007, Hib vaccine was finally approved by the Ministry of Health, Labour and Welfare and has been become available for not only regular but also voluntary vaccination<sup>17</sup>.

Based on these social circumstances, we summarized the clinical presentations of Hib meningitis including BLNAR that we observed at our hospital, and we insist on the necessity to introduce a regular vaccination of the Hib vaccine in Japan in this article.

## PATIENTS AND METHODS

The subjects consisted of 8 patients with acute purulent meningitis caused by Hib who were hospitalized at Dokkyo Medical University Hospital during the 7-year period from January 2000 to December 2006. Acute purulent meningitis was clinically diagnosed based on the increase in the number of spinal fluid cells and the results of bacterial cultivation of the spinal fluids. The following five factors were retrospectively studied in each subject based on our hospital's medical records : 1. gender, age of onset, time of onset, the presence or absence of underlying diseases : 2. differences between the results of the rapid diagnoses by latex agglutination reaction (Applied Bio-Rad Ltd, PASTOREX<sup>®</sup>. MENINGITIS, France) and the general cultivation of bacteria : 3. analysis the Hib genotypes, the variation of the penicillin-binding protein (PBP) gene<sup>1,2</sup> ; 4. antibiotics used ; and 5. the presence or absence of subdural lesions with others.

## RESULTS

The results of summarizing the clinical courses of all 8 subjects are shown in (Table 1).

### 1. Gender, age, time of onset, presence or absence of underlying disease

The gender and age of onset of the 8 patients were 6 for boys and 2 for girls. The distribution of the age of onset was determined as 1 month after birth at the youngest and 7 years 0 months after birth at the oldest, and the median was 20 months. Of these, 5 patients were infants who were under 1 year old. The months of development were March and June in 7 patients. As for the presence or absence of a background underlying disease, a 7 year and 0 month old girl had cerebral palsy compounded by trouble with a ventriculoperitoneal shunt. One patient was a newborn baby, but this does not apply as an underlying disease.

### 2. Rapid diagnosis by latex agglutination reaction with Hib

Rapid diagnoses by latex agglutination reaction using a rapid kit (Fig. 1) were made in 5 of 8 patients. Two of the patients showed no agglutination, so a rapid diagnosis could not be determined. The general cultivation of bacteria in the spinal fluids revealed Hib in all of the patients.

### 3. analyze the genotypes<sup>1,2</sup>

We requested the Graduate School of Infection Control Sciences, Kitasato Institute for Life Sciences, to analyze the genotypes only in 4 patients. The results showed BLNAR with the variation of the PBP-3 gene in 4 patients.

### 4. Treatment

The use of antibiotics was immediately initiated in all of the patients. The types of initial antibiotics that were used included ABPC+CTX in 3 patients and CZOP+AMK in 1 patient, PAPM/BP in 2 patient, MEPM in 1 patient and MEPM+CTR in 1 patient. The dosages of the antibiotics that were used consisted of 2 increments of 120 mg/kg/day of MEPM, 3 increments of 200 mg/kg/day of CTX, 2 increments of 200 mg/kg/day of ABPC, 2 increments of 100 mg/kg/day of PAPM/BP, 1 increment of 100 mg/kg/day of CZOP and 8 mg/kg/day of AMK, respectively.

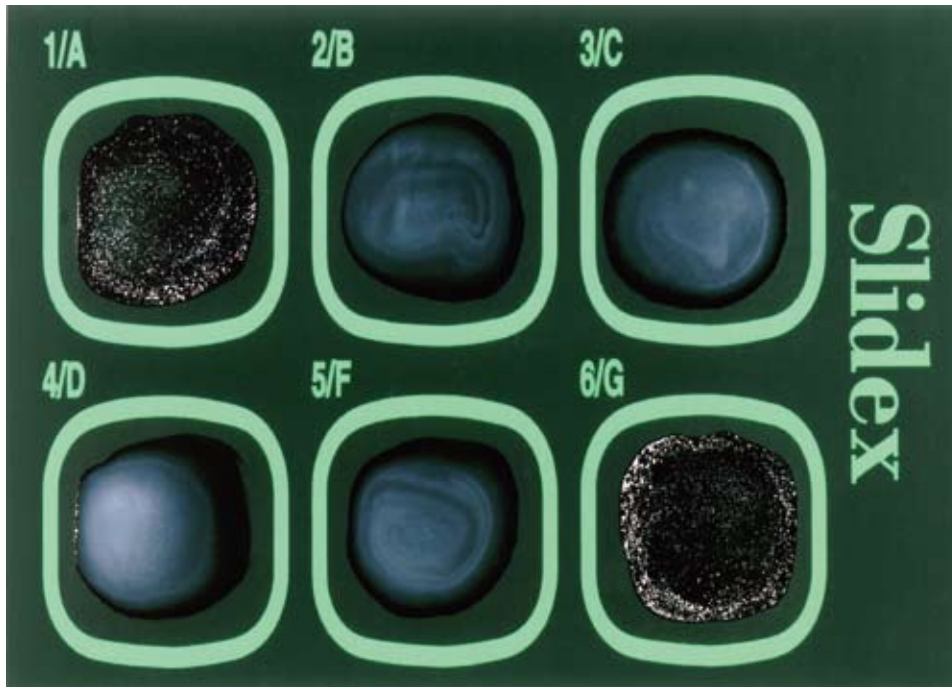
In 7 of 8 patients, dexamethasone was used before each administration of the antibiotics with a dosage of 4 increments of 0.6 mg/kg/day. The period of adminis-

**Table 1** Clinical features with subdural lesions on MRI in 8 cases with childhood onset *Haemophilus influenzae* type b meningitis

Case No.	Age of onset/sex (admission month)	Underlying disease	Cerebrospinal fluid cell count/ mm <sup>3</sup> (on admission)	Cerebrospinal fluid protein (mg/dl)	Type of Hib (Latex agglutination reaction)	Minimal inhibitory concentration for ABPC (mg/ml)	Type of subdural lesions (diagnosed days from admission on brain MRI)	Antibiotics	Dexamethasone (0.15 mg/kg × 4/day)	Surgery	Complication	Prognosis
1	0y11m/boy (May)	—	7,712	132	ND	ND	subdural hygroma (9)	ABPC+CTX	4 days 3 days	ND	—	normal development
2	7y0m/girl (June)	cerebral palsy	ND	ND	ND	ND	subdural abscess (1)	CZOP+AMK	NU NU	ventriculo peritoneal shunt evulsion	epilepsy	severe psychomotor development
3	0y3m/boy (May)	—	9,410	123	ND	0.25	subdural hygroma + abscess (4)	ABPC+CTX → MEPM → CTX → CTRX → CP	3 days NU	subdural taps from anterior frontal	convulsion, epilepsy, ventricle dilatation	normal development
4	1y11m/girl (November)	—	20,701	356	BLNAS (negative)	0.25	subdural hygroma (18)	ABPC+CTX	4 days 3 days	ND	SIADH	normal development
5	0y6m/boy (May)	—	5,480	166	BLNAR (positive)	2	subdural hygroma (15)	PAPM/BP → MEPM	4 days NU	ND	convulsion, epilepsy	hyperactivity, brain atrophy
6	0y1m/boy (March)	—	34,000	310	BLNAR (positive)	1	subdural hygroma + abscess (15)	MEPM → CTX → MEPM → CP	4 days 3 days	subdural taps from anterior frontal	convulsion, SIADH, DIC	normal development
7	0y3m/boy (April)	—	6,680	359	BLNAR (negative)	2	subdural hygroma (4)	PAPM/BP → MEPM+CTX	3 days 3 days	subdural taps from anterior frontal	SIADH	normal development
8	2y6m/boy (May)	—	3,750	325	BLNAR (positive)	4	subdural abscess (10)	MEPM+CTRX	4 days NU	ND	DIC, SIADH, HHV-6 infection	normal development

**Abbreviations :**

ABPC (ampicillin), CTX (cefotaxime sodium), CZOP (cefazopran hydrochloride), AMK (amikamycin), PAPM/BP (panipenem/betamipron), MEPM (meropenem hydrate), CTRX (ceftriaxone sodium), CP (chloramphenicol with oral administration), BLNAR ( $\beta$ -lactamase negative ampicillin resistance), BLNAS ( $\beta$ -lactamase negative ampicillin sensitive), Hib (*Haemophilus influenzae* type b), MRI (magnetic resonance imaging), NU (not use), ND (not done), SIADH (syndrome of inappropriate secretion of antidiuretic hormone), DIC (disseminated intravascular coagulopathy), HHV (human herpes virus)



**Figure 1** Latex agglutination reaction using a rapid kit showed agglutination reaction to Hi in patient No.5. (1/A : control with Haemophilus influenza type b, 2/B : Streptococcus pneumoniae, 3/C : Escherichia coli, 4/D : Neisseria meningitides, 5/F : group B streptococci, 6/G : Haemophilus influenza type b)

tration of dexamethasone was 2 patients in 3 days and 5 patients in 4 days.

The other concomitantly used drugs included mannitol, and midazolam that was continuously administered in subjects in whom convulsive symptoms were observed.

##### 5. Subdural lesions and neurological prognoses

Several brain CT or MRI examinations were performed at appropriate times in all of the patients, and the complication of the development of subdural lesions was neuro-radiologically studied. The results showed the compounded development of subdural lesions in all of 8 patients. The details consisted of subdural abscess in 4 patients and subdural hygroma in 4 patients. The time of onset of subdural hygroma or abscess was 1 to 18 days after the initiation of treatment, which was diagnosed via neuro-radiological imaging (Fig. 2).

Four patients with subdural abscess were initially treated with antibiotics that improved general conditions but failed to reduce the abscesses in size. Three out of 4 patients with hematoma, drainage was per-

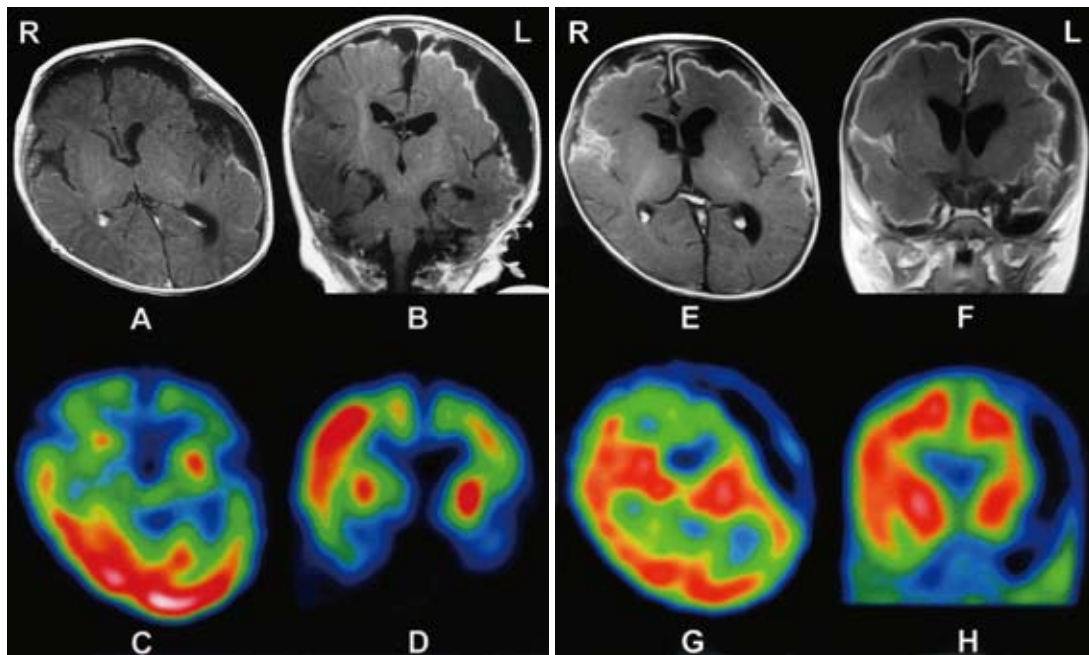
formed with subdural taps and 2 increments of 100 mg/kg/day of CP were orally administered as part of antibiotics treatment, after which the amelioration of the subdural abscess was observed with the passage of time.

In the 4 patients in whom subdural hygroma was observed, the continued administration of the already administered antibiotics ameliorated the hygroma.

As for neurological prognoses, concomitant symptoms that were observed within the observation period until September 2010 included epileptic seizure in 4 patients, auditory disorder in 0, and death in 0 patients.

## DISCUSSION

We studied 8 patients with Hib meningitis in childhood. We made early diagnoses of Hib using spinal fluid via the latex method and treated with appropriate antibiotics according to sensitivity, but all of the patients developed subdural lesions. Our cases indicate that it is impossible to avoid the complication of developing subdural lesions with the administration of the currently available antibiotics alone with Hib meningi-



**Figure 2** Brain MRI FLAIR images (spin echo : TR=9,000 msec/TE=105 msec) with contrast agent (A/B : patient No.7, E/F : patient No.6) (C/D : patient No.7, G/H : patient No.6) revealed enhancement image of miginx and severe subdural effusion in patients with Hib meningitis.  $^{99m}\text{Tc}$ -ECD SPECT (C/D : patient No.7, G/H : patient No.6) exhibited hypoperfusion cortical areas consisted with adjacent to the subdural effusion.

tis.

Regarding the diagnosis of Hib meningitis, it is necessary to be performed in spinal fluid to detect the causative bacterium, and appropriate treatment was given accordingly. Meanwhile, until the causative bacterium was determined, treatment with an antibiotic was administered after the causative bacterium with empiric therapy. We performed latex agglutination using spinal fluid to make an earlier diagnoses of Hib and initiated treatment with antibiotics. This kit was very useful, because very early diagnoses of causative bacteria that induced the bacterial infectious diseases could be made within about 15 minutes, and differential diagnoses of pneumococcal organisms, *Escherichia coli*, meningococcus, etc., could also be simultaneously made in addition to Hib<sup>18~20</sup>. For antimicrobial therapy, the ampicillin, is generally regarded as effective, but in recent years, ampicillin-resistant Hib has become a problem. In our patients, BLNAR was also observed in 4 patients. BLNAR was first reported in 1980 due to the increased use of treatment with several antibiotics. PBP-3 of penicillin-binding protein is involved in the mechanism of acquiring resistance. In Ja-

pan, Hasegawa *et al.* reported in 2004 that 21.3% of the *Haemophilus influenzae* that was investigated in 2002 showed BLNAR, which is a problem, because the detection rate is very high<sup>11,17</sup>. After we diagnosed Hib according to the latex rapid reaction, we suspected BLNAR and selected antibiotics such as MEPM and PAPM/BP as well as the fourth- or third-generation cephalosporins such as CZOP and CTX. Dexamethasone therapy was reported<sup>21~23</sup> and was determined as effective in preventing auditory damage<sup>8,9</sup>. However, we could not avoid the complications of subdural lesions in all 8 patients.

It has been reported that the complication of subdural lesions is often observed in Hib meningitis<sup>24,25</sup>, and methods of treating it often become problematic during the course of Hib meningitis. All of our Hib meningitis exhibited subdural lesions. Anzai *et al.* reported 9 cases of Hib meningitis with subdural abscess and performed subdural taps in 4 patients, and they concluded earlier intervention with subdural taps to the subdural abscess might be prevented additional complications<sup>26</sup>. According to our patients No.4, 5, 8 with only subdural hygroma showed amelioration

through continuous treatment with antibiotics. In general, the expression of subdural abscess indicates insufficient treatment with antibiotics in meningitis. However, in the patients with subdural abscess, the lesions did not ameliorate with the administration of antibiotics alone, so we performed subdural taps in patients No. 3, 6, 7. After we employed several subdural taps accordingly, amelioration of the subdural abscess was clinically observed.

The subdural lesions that were observed with diagnostic imaging showed a contrast effect along the area affected by meningitis. This is an image of meningitis being capsulated due to inflammation of the meninx, thus forming an abscess therein. When the inflammation of capsulated meningitis is observed, it is believed that the effect of an antibiotic did not extend to the inside of the capsule.

CP shows high central transfer and is particularly administered for Hib meningitis<sup>27,28</sup>. Thus, the oral administration of CP was selected as an antibiotic in patients No. 3, 6. Side effects include liver, kidney, and gastrointestinal damage, hematopoietic damage, aplastic anemia, and Gray syndrome, but these side effects were not observed in our subjects. Sofue-Hiraiwa *et al.* reported successful treatment of four infants with subdural lesion with CP in Hib meningitis. Among them, two patients developed leucopenia and hypersensitive rash during the course of treatment, although these adverse effects were promptly eliminated when the drug was stopped<sup>29</sup>. Intravenous administration can also be selected as a method of administering CP, but it has been reported that oral administration can maintain a higher blood concentration<sup>30</sup>. The number of our patients was small, but in our patients alone, the concomitant use of subdural taps and CP was one of the methods that were used to control a subdural abscess that had developed as a complication of Hib meningitis.

In 2007, the preventive vaccination with Hib vaccine was introduced in Japan, but the alternative is a voluntary method. Physicians who are involved with infections, must inform the public of the significance of Hib vaccines to eliminate Hib infections in Japan and must petition the government to have such modalities included as regular vaccinations. It has been indicated that Hib vaccines are very effective in preventing the

development of Hib meningitis and Hib infections. At present, it is speculated that 8.6 to 8.9 people per 100,000 people who are below the age of 5 years old are affected with bacterial meningitis per year in Japan<sup>15</sup>. Vaccination of the Hib is recommended for younger children under 5 years old, but we treated Hib meningitis in a 7-year-old in patient No.2. The Japan Pediatric Society submitted a requisition paper to the Ministry of Health, Labour and Welfare in June 2005, requesting early approval. At the end of January 2007, the production of an Hib vaccine (ActHIB<sup>®</sup>) was finally approved<sup>17</sup>. In the United States, regular vaccination with Hib vaccines was introduced in 1987, thus resulting in a dramatic decrease to 1/100 of the infections caused by Hib<sup>3,7</sup>. In the UK, vaccines were approved in 1992, and the prevalence of Hib in patients under 5 years old decreased to 0.6 per 100,000 people in 1998<sup>3,4</sup>. With the approval of Hib vaccine in Japan as a turning point, it is expected that Hib meningitis in Japan will dramatically decrease in the near future. However, Hib vaccination is currently voluntary. It is preferable for Hib vaccination to be incorporated into regular vaccinations as a government policy. To prevent the Hib meningitis associated with subdural lesions, attention should be paid to the promotion of preventive vaccinations of Hib vaccine.

*Acknowledgement.* We would like to thank Kimiko Ubukata, the Graduate School of Infection Control Sciences, Kitasato Institute for Life Sciences for executing genotype analysis of Hib and thanks to Katsuko Okuzumi, Dokkyo Medical University for her valuable supervision.

## REFERENCES

- 1) Ubukata K, Chiba N, Hasegawa K, Shibasaki Y, Sunagawa K, Nonoyama M, et al : Differentiation of beta-lactamase-negative ampicillin-resistant *Haemophilus influenzae* from other *H. influenzae* strains by a disc method. *J Infect Chemother* **8** : 50-58, 2002.
- 2) Ubukata K, Shibasaki Y, Yamamoto K, Chiba N, Hasegawa K, Takeuchi Y, et al : Association of amino acid substitutions in penicillin-binding protein 3 with  $\beta$ -lactam resistance in  $\beta$ -lactamase-negative ampicillin resistant *Haemophilus influenzae*. *Antimicrob Agents Chemother* **45** : 1693-1699, 2001.

- 3) Jillian M, Zeinab M, Thomas R. TH, Samir S.S. Corticosteroids and mortality in children with bacterial meningitis. *JAMA* **299** : 2048-2055, 2008.
- 4) Theodoridou MN, Vasilopoulou VA, Atsali EE, Pangalis AM, Mostroy GJ, Syriopoulou VP, et al : Meningitis registry of hospitalized cases in children : epidemiological pattern of acute bacterial meningitis throughout a 32-year period. *BMC Infect Dis* **30** : 101, 2007.
- 5) Santosham M, Reid R, Ambrosino DM, Wolff MC, Almedio-Hill J, Prihs C, et al : Prevention of haemophilus influenzae type b infections in high-risk infants treated with bacterial polysaccharide immune globulin. *N Engl J Med* **317** : 923-929, 1987.
- 6) van de Beek D, de Gans J, McIntyre P, Prasad K : Corticosteroids for acute bacterial meningitis. *Cochrane Database Syst Rev*. CD004405 : 1, 2007.
- 7) Sharip A, Sorvillo F, Redelings MD, Mascola L, Wise M, Nguyen DM : Population-based analysis of meningococcal disease in the United States : 1990-2002. *Pediatr Infect Dis J* **25** : 191-194, 2006.
- 8) Koomen I, Grobbee DE, Roord JJ, Donders R, Jennekens-Schinkel A, van Furth AM : Hearing loss at school age in survivors of bacterial meningitis : assessment, incidence, and prediction. *Pediatrics* **112** : 1049-1053, 2003.
- 9) Wellman MB, Sommer DD, McKenna J : Sensorineural hearing loss in postmeningitic children. *Otol Neurotol* **24** : 907-912, 2003.
- 10) Nariai A : Prevalence of beta-lactamase-nonproducing ampicillin-resistant *Haemophilus influenzae* and *Haemophilus influenzae* type b strains obtained from children with lower respiratory tract infections. *J Infect Chemother* **13** : 396-399, 2007.
- 11) Hasegawa K, Kobayashi R, Takada E, Ono A, Chiba N, Morozumi M, et al : High prevalence of type b beta-lactamase-non-producing ampicillin-resistant *Haemophilus influenzae* in meningitis : the situation in Japan where Hib vaccine has not been introduced. *J Antimicrob Chemother* **57** : 1077-1082, 2006.
- 12) Bakir M, el-Khadir A, Devadas K, Farrukh AS, Udu-man SA : *Haemophilus influenzae* type b diseases in children : a pre-vaccination study. *East Mediterr Health J* **7** : 597-603, 2001.
- 13) Pedersen TI, Howitz M, Ostergaard C : Clinical characteristics of *Haemophilus influenzae* meningitis in Denmark in the post-vaccination era. *Clin Microbiol Infect* **16** : 439-446, 2010.
- 14) Mikoluc B, Piotrowska-Depta M, Pietrucha B, Bernatowska E : *Haemophilus influenzae* type b-active prevention. *Med Wieku Rozwoj* **12** : 661-665, 2008.
- 15) Razafindralambo M, Ravelomanana N, Randriamiharisoa FA, Migliani R, Clouzeau J, Raobijaona H, et al : *Haemophilus influenzae*, the second cause of bacterial meningitis in children in Madagascar. *Bull Soc Pathol Exot* **97** : 100-103, 2004.
- 16) Brouwer MC, Tunkel AR, van de Beek D : Epidemiology, diagnosis, and antimicrobial treatment of acute meningitis. *Clin Microbiol Rev* **23** : 467-492, 2010.
- 17) Miyazaki C : Hib vaccine. *Nippon Rinsho* **66** : 1985-1989, 2008.
- 18) Kim KS : New diagnostic and therapeutic options in bacterial meningitis in infants and children. *Minerva Pediatr* **61** : 531-548, 2009.
- 19) Chanock SJ, Toltzis P, Wilson C : Cross-reactivity between *Stomatococcus mucilaginosus* and latex agglutination for cryptococcal antigen. *Lancet* **342** : 1119-1120, 1993.
- 20) Kaplan NM : The value of latex particle agglutination test for rapid detection of bacterial antigens in the cerebrospinal fluid. *Saudi Med J* **29** : 774-775, 2008.
- 21) Chaudhuri A : Adjunctive dexamethasone treatment in acute bacterial meningitis. *Lancet Neurol* **3** : 54-62, 2004.
- 22) Nguyen TH, Tran TH, Thwaites G, et al : Dexamethasone in Vietnamese adolescents and adults with bacterial meningitis. *N Engl J Med* **357** : 2431-2440, 2007.
- 23) de Gans J, van Beek D : Dexamethasone in adults with bacterial meningitis. *N Engl J Med* **347** : 1549-1556, 2002.
- 24) Fernandez-Jaen A, Calleja-Perez B, Martinez-Bermejo A, Borque C, Pascual-Castroviejo I : Subdural effusion in type B *Haemophilus influenzae* meningitis. A study of 38 cases. *Rev Neurol* **25** : 1886-1889, 1997.
- 25) Imataka G, Miyamoto K, Fujiyama Y, Mitsui M, Yoshida A, Yamanouchi H, et al : Acute purulent meningitis associated with chronic subdural hematoma and subdural hygroma. *Turk J Pediatr* **49** : 437-440, 2007.
- 26) Anzai Y, Kamiyama T, Kamiya H, Fujita M, Ohya T : Clinical features during the acute phase in the complicated cases with bacterial meningitis. *J Jpn Pediatr*

- Soc **109** : 492-498, 2005.
- 27) Pickering LK, Hoecker JL, Kramer WG, Kohl S, Cleary TG : Clinical pharmacology of two chloramphenicol preparations in children : sodium succinate (iv) and palmitate (oral) esters. *J Pediatr* **96** : 757-761, 1980.
- 28) Rensimer ER, Pickering LK, Ericsson CD, Kramer WG : Sequential CSF concentration of chloramphenicol after administration of oral chloramphenicol palmitate. *Lancet* **1** : 165, 1981.
- 29) Sofue-Hirakawa A, Hasegawa S, Atsumi M, Itomi S, Hatano S, Fukasawa T, et al : Four infants developed subdural empyema as complications of Haemophilus influenza meningitis : effective treatment with chloramphenicol. *J Jpn Pediatr Soc* **113** : 1219-1227, 2009.
- 30) Imataka G. Letter to editor : Yamashita S *et al.* Successful treatment with chloramphenicol in an infantile case of bacterial meningitis with subdural abscess. *J Jpn Pediatr Soc* **113** : 1469, 2009.