

Case Report

Lennox-Gastaut Syndrome Associated with Unilateral Hemispheric Porencephaly

George Imataka¹, Masahiro Ogino², Yoshiyuki Watabe¹, Shigeko Kuwashima³,
Teisuke Hashimoto³ and Osamu Arisaka¹

*Department of Pediatrics¹, Neurosurgery² and Radiology³,
Dokkyo Medical University School of Medicine*

SUMMARY

We report an 18 year-old male with a hemispheric large porencephaly who demonstrated symptomatic West syndrome and then developed into Lennox-Gastaut syndrome. An electroencephalogram showed an asymmetrical high voltage slow spike and wave discharges only on the right side as a side of porencephalic hemisphere. Interestingly, on the opposite side of the porencephalic hemisphere, an electroencephalogram showed a low amplitude background activity in general. In this unique features both right side hemispheric porencephaly and asymmetric high voltage slow spike and waves due to Lennox-Gastaut syndrome, the porencephalic hemisphere due to cortical parenchymal loss may be more affected than the other hemisphere by epileptiform discharge in this patient.

Key Words : Lennox-Gastaut syndrome (LGS), porencephaly, electroencephalogram, magnetic resonance imaging, single photon emission computed tomography

INTRODUCTION

West syndrome due to unilateral radiological lesions has been often reported¹⁾. However, Lennox-Gastaut syndrome (LGS) with unilateral hemispheric MRI abnormalities is less frequently observed, in spite of the fact that West syndrome can sometimes evolve into LGS^{1~4,6)}.

In this report, we document a rare case of a large unilateral porencephaly that developed into West syndrome followed by LGS and then discuss the relation between clinically very unique patient's EEG findings with demonstrable unilateral diffuse high voltage slow

spike and wave discharges.

CASE REPORT

The patient was born by spontaneous delivery in the 36th week of pregnancy with no asphyxia. His birth weight was 1,618 g. During pregnancy, his mother had neither infection nor received any medicine. From early infancy, his developmental milestones were delayed. Neck stabilization was observed at 4 months, sitting at 9 months, walking at 17 months. At 1.5 year-of-age, motor paralysis was observed in the left upper and lower limbs. Brain CT showed a large porencephaly lesion on the right side.

At the age of 2 years and 3 months, atonic and generalized tonic clonic seizures were frequently observed. An EEG showed asymmetrical right side dominant high amplitude hypsarrythmia. G-band chromosomal analysis and amino acid, organic acid, and lactic acid levels³ were all normal, and a diagnosis

Received March 2, 2010 ; accepted May 19, 2010

Reprint requests to : George Imataka, MD.

Department of Pediatrics, Dokkyo Medical
University School of Medicine, Mibu, Tochigi
321-0293 Japan

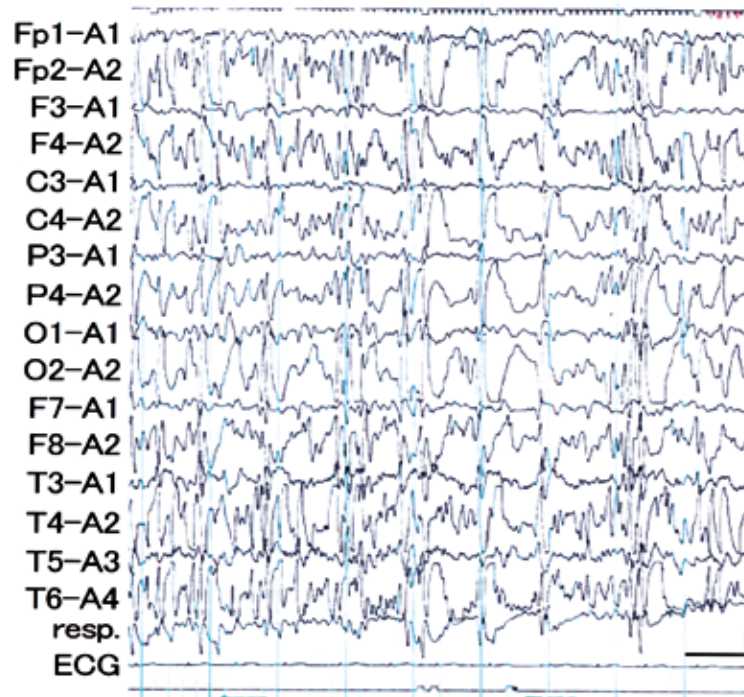


Fig. 1 Electroencephalogram : EEG

Interictal EEG revealed abnormal asymmetric 1.5 Hz to 2 Hz diffuse slow spike and wave discharges predominantly in the frontal area in the right hemisphere, which was consistent with the EEG features of asymmetric Lennox-Gastaut syndrome.

of symptomatic West syndrome was made. ACTH therapy (0.015 mg/kg/day) by intramuscular injection was administered for 4 weeks, then the EEG findings improved. Subsequently, the epileptic seizures were controlled by the administration of sodium valproate and vitamin B6.

At 12 years of age, he could run slowly while motor paralysis was present in the left side upper and lower limbs. His gripping dynameter showed 3 Kg on the left side and 15 Kg on the right side. Asymmetric tonic seizures developed mainly in the right upper and lower limbs. An interictal EEG showed 1.5 to 2 Hz diffuse irregular slow spikes and wave discharges on only the right side alone (Fig. 1), therefore he was diagnosed with LGS. Asymmetric tonic seizures were controlled with valproate, ethosuximide, and acetazolamide. Brain MRI showed a large porencephaly lesion in the right hemisphere (Fig. 2a, 2b). Interictal ^{99m}Tc -ECD SPECT showed a decrease in blood flow in the remaining cerebral cortex area in the right porencephalic hemisphere (Fig. 2c, 2d). Surgical treatment for epilepsy was con-

sidered, but his parents' did not consent to the surgery.

DISCUSSION

The patient showed the unique asymmetric EEG features of LGS with high voltage slow spike and wave discharges manifested only on the side of porencephalic hemisphere. Velasco et al.⁶⁾ reported a similar cases with ours, demonstrating asymmetrical EEG activity with higher amplitude spikes and waves over the various hemispheric dysplasia diagnosed with MRI in patients with LGS. The definition of diffuse slow spike and wave discharges in LGS stress the importance of bilateral synchrony^{1~4,6)}. Therefore, in this patient, the unilateral diffuse slow spike and wave discharges on only the unilateral side is not the typical EEG features of LGS. One possible explanation is that the unilateral diffuse slow spike and wave discharges EEG in our patient may originate from a cerebral cortical parenchymal loss due to large porencephaly. Interestingly, the opposite hemisphere without porencephaly showed

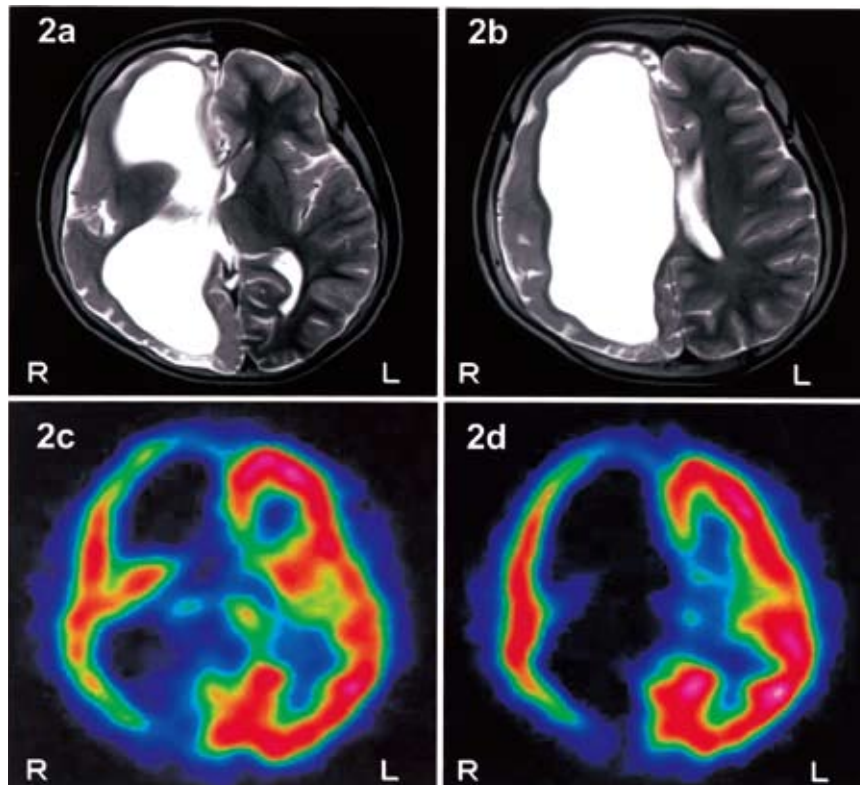


Fig. 2 Magnetic resonance imaging (2a, 2b) and ^{99m}Tc -ECD Single photon emission computed tomography : SPECT (2c, 2d)

Brain MRI : T2-weighted images (spin echo : TR=3,500 msec/TE=100 msec) revealed a large porencephaly lesion in the right hemisphere (2a, 2b). Interictal ^{99m}Tc ECD-SPECT showed a decreased perfusion of the cerebral blood flow in the right hemisphere consistent with brain MRI images of a large porencephaly.

suppressed EEG amplitude, which may be affected by the contralateral epileptiform discharges. Clinically, his asymmetric tonic seizure that occurred at 12 years-of-age, was dominantly observed on his right limbs rather than left. It may be masked by his left hemiparesis, inconsistent with the fact that his right hemisphere is covered by unique unilateral diffuse slow spike and wave discharges in this LGS. The mechanism of diffuse slow spike and wave discharges with LGS range from disorders of the bilateral cerebral cortices with disorders in the thalamus and brainstem to those of the diencephalic reticular formations⁵. We think this case is a very suitable clinical example of large hemispheric MRI anomalies with cerebral parenchymal loss with asymmetric high voltage slow spike and wave discharges in LGS.

As for surgical treatment of this patient, he can be a candidate for right hemispherotomy. Although additional evaluations, including long-term video EEG

monitoring, ictal SPECT studies and functional MRI, etc, will be needed before surgical indication, MRI clearly demonstrated diffuse right hemispheric pathology and EEG showed interictal epileptiform discharges recorded only on this side. The patient's family denied surgical consultation and the patient has not yet been sent to the presurgical evaluation.

Acknowledgement. This study was partly supported by the Dokkyo Medical University, Investigator-Investigated Research Grant (No. 2010-01-6).

REFERENCES

- 1) Dulac O, N' Guyen T : The Lenox-Gastaut syndrome. *Epilepsia* 34 Suppl 7 : S7-17, 1993.
- 2) Markand ON : Lennox-Gastaut syndrome (childhood epileptic encephalopathy). *J Clin Neurophysiol* 20 : 426-441, 2003.
- 3) Ohtahara S, Ohtsuka Y, Yamatogi Y, Yoshinaga H,

- Sato M : Prenatal etiologies of West syndrome. *Epilepsia* **34** : 716-722, 1993.
- 4) Riikonen R : Long-term outcome of West syndrome : a study of adults with a history of infantile spasms. *Epilepsia* **37** : 367-372, 1996.
- 5) Timofeev I, Grenier F, Steriade M : Spike-wave complexes and fast components of cortically generated seizures. IV. Paroxymal fast runs in cortical and thalamic neurons. *J Neurophysiol* **80** : 1495-1513, 1998.
- 6) Velasco AL, Boleaga B, Santos N, Velasco F, Velasco M : Electroencephalographic and magnetic resonance correlations in children with intractable seizures of Lennox-Gastaut syndrome and epilepsy partialis continua. *Epilepsia* **34** : 262-270, 1993.