

|||||
Case Report
|||||

Anterior Spinal Artery Syndrome in 13-year Old boy : A Case Report

George Imataka¹, Reina Yamazaki², Shigeiko Kuwashima²,
Hideo Yamanouchi¹ and Osamu Arisaka¹

Department of Pediatrics¹ and Radiology², Dokkyo Medical University School of Medicine

SUMMARY

We herein report a rare case of a child patient with anterior spinal artery syndrome. The patient presented with mobility impairment in the lower limbs after suffering from a common cold. Temperature perception and pain perception were lost in both sides below the level of the fourth thoracic spine. In a thoracic spine MRI, abnormal signals were detected in the ventral side of the spinal cord below the Th3 level, thus leading to our diagnosis of anterior spinal artery syndrome. Gamma globulin therapy and steroid pulse therapy were applied concomitantly but no obvious effects were obtained. Continuing treatment with rehabilitation started for one month. Four months later, he was able to maintain a standing position and walk using a walking stick. The loss of temperature perception and pain perception in both sides below the Th4 remained.

In the present case, movements in daily life became possible through the effects of rehabilitation. However, an impairment in the patient's temperature and pain perception remained, and thus close attention is required for various disorders and in daily life.

Key Words : anterior spinal artery syndrome, child, magnetic resonance imaging, steroid pulse, gamma globulin therapy

INTRODUCTION

Anterior spinal artery syndrome (ASAS) is a syndrome that develops as (1) rapid paraplegia below the affected area, (2) a dissociable sensomobile disorder below the affected area, and (3) a vesicorectal disorder due to a disorder in blood circulation and occlusion of the anterior spinal artery, which dominates 2/3 of the ventral side of the spinal cord¹⁾. There are occasional reports of adult patients²⁾ but child patients are

rare. We experienced the case of a 13-year-old boy with this syndrome and herein report his clinical course.

CASE REPORT

The patient was a 13-year-old boy whose body height was 165 cm and body weight was 75 kg. His development was normal, his family history included allergies, and he had a history of treatment for asthma. The season was spring. In the morning of the third day of his cold symptoms, he experienced discomfort in his knees. He walked to the bathroom by himself, but after urinating, he suddenly lost all strength in his lower limbs and could not walk. He was referred to our hospital for a complete examination by a nearby orthopedics department.

Received March 10, 2008 ; accepted April 10, 2009

Reprint requests to : George Imataka M.D.

Department of Pediatrics, Dokkyo Medical
University School of Medicine, Mibu, Tochigi,
321-0293 Japan.

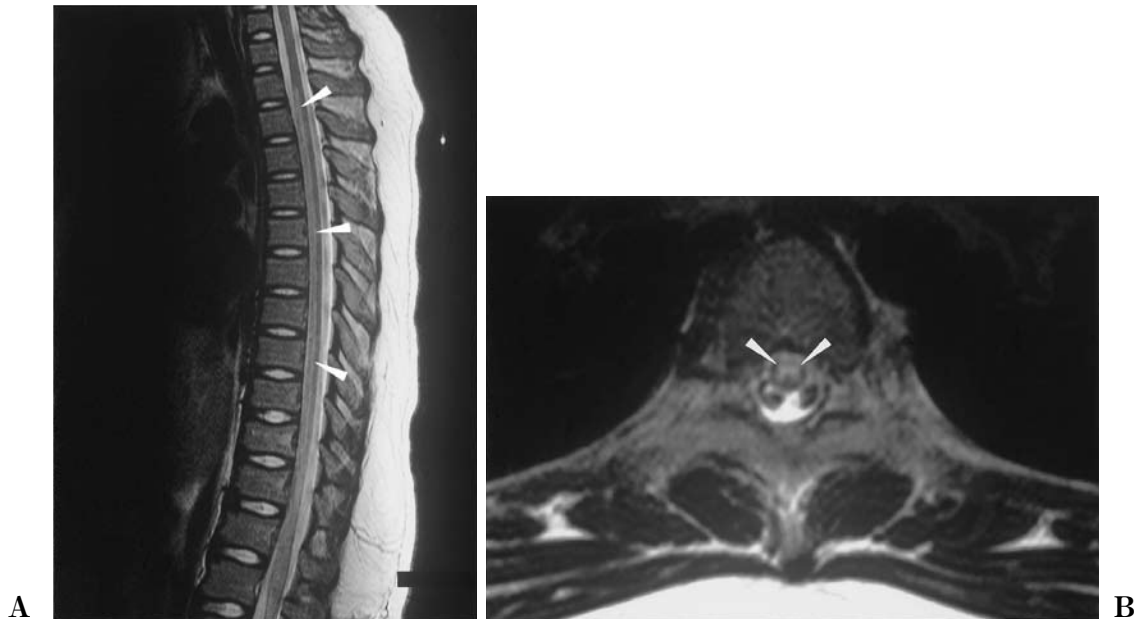


Figure 1 Spinal Magnetic Resonance Imaging

A lesion in T2 weighted image (A) passing symmetrically, continuously, and longitudinally through the intraventricular spinal cord at the Th2/3-Th11 level was observed. Horizontal cross-section through the spinal cord at the Th5 level (B). An abnormally signal was observed in the area indicated by the arrow.

His consciousness was clear during consultation. He had a cough and mild reddening in his pharynx. The movements and senses of his face, eyeballs, neck, and upper limbs were normal, but his temperature perception and pain perception were lost below his third thoracic spine, though the position perception and vibration perception of the affected area were maintained. In terms of muscle movements below the affected area, he was unable to move either side of his abdominal area or his lower limbs, and a manual muscle test showed only the extensor digitorum longus muscle of his right lower limb was Level 1 (trace) while the other muscles were Level 0. He was unable to urinate or defecate by himself. Abdominal reflexes, patella tendon reflexes, and Achilles tendon reflexes in both sides were negative, though the Babinski's reflex in both sides was positive.

The results of a general blood test were normal. He tested negative for mycoplasma, Epstein-Barr virus, and cytomegalovirus antibody levels. He was also negative for anticardiolipin antibodies. His IgE was 480. The results of the general spinal fluid test were normal. No oligoclonal band was detected. Myelin basic protein levels were normal. His IgG index was 0.352. No virus was separated from his spinal fluid. Cardiac

ultrasonography also showed normal results.

The results of the brain MRI and MRA were normal. In the thoracic spinal MRI (Fig. 1A, 1B), abnormal signals were detected in the Th2/3-Th11 level of the intraventricular spinal cord and he was thus diagnosed to have ASAS.

We conducted 5-day 400-mg/Kg gamma globulin therapy and 2-day 30-mg/kg steroid pulse therapy but no obvious clinical improvements were observed. An elastic hose was used to prevent venous thrombus. He had no urge to defecate and was thus given an enema. Urethral catheterization was used for urination. Rehabilitation began which was conducted mornings.

After one month, the deep tendon reflexes of the lower limbs increased to 3+ in both his right and left limbs. The Babinski's reflex and Chaddock's reflex were positive in both sides. Muscle strength improved to 2+ in the iliopsoas, 2+ in both quadriceps femoris muscles and the hamstrings, and 3+ in the anterior tibial muscles, but he was unable to urinate by himself.

Two months later, he moved to a community rehabilitation center to undergo more intensive rehabilitation and was consequently able to maintain a standing position and walk using a walking stick after four months.

Table 1 Report of anterior spinal artery syndrome of childhood in Japan from 1994 to 2008.

Case No.	references No.	age	sex	initial symptom	abnormal intensity area of MRI	treatment	prognosis (walking capability)	etiology
1	16)	7y	F	pain in large thigh on both sides	Th7~Th12	steroid pules, aspirin hybaroxia, edaravone	Movement disorder of both lower limbs Th7 or less. (It is not possible to walk).	uncertain
2	17)	15y	F	backache → both paralyses of the lower extremities	Th3~Th8	steroid pules, glyceol	The disorder of the sensation for pain and temperature remains. (walking with brace)	type II diabetes
3	18)	25days	F	Both hands are not moved	C5~Th1	artificial ventilation	severe psychomotor retardation (It is not possible to walk.)	fetal hydrops
4	19), 20)	11y	F	Breathing difficulties occurred on the fifth cold day.	C4~C6	artificial ventilation steroid pulse, glyceol	complete paralysis of both arms (walking with brace)	uncertain
5	20)	8y	F	Quadriplegia + breathing difficulties after two hours falls	C4~C8	details are uncertain	spastic paralysis of left arm and flaccid paralysis of right arm (walking without brace)	uncertain
our case	—	15y	M	Walking difficulties occurred on the third cold day morning.	Th2/3~Th11	IVIg, steroid pulse vitamin B	The disorder of the sensation for pain and temperature remains. (walking without brace)	uncertain

One year later, he was able to walk long distances and urinate by himself. However, the loss of temperature perception and pain perception in both sides below Th4 remained. He remained unaware of bruises caused by falling down during his daily activities, and thus close attention was required.

Two years after the initial onset, he visited the outpatient department complaining of a fever and acute diarrheal symptoms although he had no subjective symptoms of abdominal pain due to his impaired pain perception. We observed an increase in inflammatory reaction and inpatient hospital care was required due to acute bacterial gastroenteritis.

At present, he is still continuing rehabilitation while attending high school.

DISCUSSION

The spinal cord consists of three arteries : two posterior spinal arteries and one anterior spinal artery. Therefore, a disorder in the blood circulation of the anterior spinal artery creates a situation with no substitute path for blood circulation and it often results in critical long-term symptoms of spinal cord infarction, thus creating the problem of severe aftereffects. In

adult cases of ASAS, it normally develops in the elderly after surgery for aortic aneurysm due to, for example, thrombus or embolus caused by arterial sclerosis, or compression caused by an extramedullary lesion. However, this case was that of a rare child patient. The cause of many pediatric cases of ASAS is unknown. The cause of ASAS in our case, who was a 13-year-old patient, was also unknown. To the extent of our search, there were 5 cases in Japan during the past 15 years from 1994 to 2008. These 6 cases, including this case, are shown in the order of publication (Table 1)^{16~20)}. The cause could not be clearly identified in any of these 6 cases as shown in the table. The underlying disease that may have been involved in the onset of ASAS was found in 2 cases, wherein Case 2 was type II diabetes and Case 3 was a newborn case that was under artificial ventilation due to fetal edema.

ASAS is diagnosed through abnormal signals in spinal MRI. Normally, in anterior spinal artery syndrome, high-intensity areas of an enlarged spinal cord that are well defined from the back side are detected in several segments of the vertebral bodies in MRI and in the abdominal sides of the affected area in a T2 weighted image. In this patient, abnormal signals were

observed in at least nine vertebral bodies, and the affected area was broad.

The only treatment methods for ASAS are systemic therapies, but there are reports of thrombolytic therapy with urokinase at an early stage being effective in some adult patients. However, there is no effective treatment method for ASAS in children. We performed gamma globulin therapy and steroid pulse therapy for their immunological mechanisms and anti-inflammatory effects but obtained no obvious effect. However, in the daily life of this patient, the loss of temperature perception and pain perception below his thoracic spine has remained. It is necessary to provide lifestyle guidance to compensate for his permanent insensitivity to pain and prevent, for example, injuries in his lower limbs without the patient himself realizing and deteriorations of gastroenteritis symptoms resulting in the need for inpatient hospital care.

Acknowledgement. This study was partially supported by the Ministry of Education, Culture, Sports, Science and Technology (MEXT) KAKENHI No. 18790733 Grant-in-Aid for Young Scientists (B) and the Dokkyo Medical University, Investigator-Initiated Research Grant (No. 2010-01-6).

REFERENCES

- 1) Chachad S : Anterior spinal artery syndrome in a 16-year-old male. *W V Med J* **102** : 27-28, 2006.
- 2) Hakimi KN, Massagi TL : Anterior spinal artery syndrome in two children with genetic thrombotic disorders. *J Spinal Cord Med* **28** : 69-73, 2005.
- 3) Suzuki Y, Toribe Y, Idoguchi R, Ogawa K, Mano T : A neonatal case of anterior spinal artery syndrome presenting with bilateral arm paresis. *No To Hattatsu* **37** : 65-69, 2005.
- 4) Servais LJ, Rivelli SK, Dachy BA, Christophe CD, Dan B : Anterior spinal artery syndrome after aortic surgery in a child. *Pediatr Neurol* **24** : 310-312, 2001.
- 5) Ramelli GP, Wyttenbach R, von der Weid N, Ozdoba C : Anterior spinal artery syndrome in an adolescent with protein S deficiency. *J Child Neurol* **16** : 134-135, 2001.
- 6) Uchida K, Kobayashi S, Sato R, Nakajima H, Yayama T, Kokubo Y, et al : Anterior spinal artery syndrome complicating massive paravertebral abscess. *J Orthop Sci* **13** : 86-88, 2008.
- 7) Arai S, Utsunomiya H, Wakugawa Y, Uwadoko T : A case of spinal infarction caused by disc herniation. *Brain Nerve* **59** : 997-1000, 2007. (Japanese)
- 8) Pantet O, Frischknecht R, Croquelois A : Sudden paraplegia due to an anterior spinal artery syndrome during the cause of *Staphylococcus aureus* septicemia. *Cerebrovasc Dis* **24** : 307-309, 2007.
- 9) Aylwin C, Tai N, Walsh M : Anterior spinal artery syndrome after abdominal stabbing and resuscitative thoracotomy. *J Trauma* **62** : 526-528, 2007.
- 10) Tuncel G, Ozalp G, Canoler O, Cakmak H, Ergeneci A, Kadiogullari N : Anterior spinal artery syndrome after thoracic surgery. *J Coll Physicians Surg Pak* **25** : 819-820, 2005.
- 11) Yoshida S, Nitta Y, Oda K : Anterior spinal artery syndrome after minimally invasive direct coronary artery bypass grafting under general combined epidural anesthesia. *Jpn J Thorac Cardiovasc Surg* **53** : 230-233, 2005.
- 12) Dinca-Avarvarei L, Valdes-Cruces JC, Quesada-Garcia M, Izquierdo G : The value of diffusion magnetic resonance imaging in diagnosing infarction of the anterior spinal artery. *Rev Neurol* **40** : 282-285, 2005. (Spanish)
- 13) Odaka M, Hirata K : Anterior spinal artery syndrome due to cervical spondylosis presenting as cervical angina. *No To Shinkei* **56** : 961-963, 2004.
- 14) Takase K, Murai H, Furuya H, Ohyagi Y, Yamada T, Kira J : An adult case of primary antiphospholipid syndrome presenting recurrent anterior spinal artery syndrome. *Rinsho Shinkeigaku* **41** : 136-139, 2001. (Japanese)
- 15) Crystal Z, Katz Y : Postoperative epidural analgesia and possible transient anterior spinal artery syndrome. *Reg Anesth Pain Med* **26** : 274-277, 2001.
- 16) Taki S, Nishiyama M, Yamada S, Aketa H, Kasai Y, Uchida J : Spinal cord infarction in a child : A case report. *J Tohkai Spinal Surg* **22** : 88-90, 2008. (Japanese)
- 17) Shoji K, Takano T, Takahashi Y, Satoh H, Harada W, Yoshida H, Itou S : A case of anterior spinal artery syndrome for infarction of spinal cord. *The Journal of Tsuruokashiritu Shonai Hospital* **17** : 51-55, 2007. (Japanese)
- 18) Suzuki Y, Toribe Y, Idoguchi R, Ogawa K, Mano T :

- A neonatal case of anterior spinal artery syndrome presenting with bilateral arm paresis. *No To Hattatsu* **37** : 65-69, 2005. (Japanese)
- 19) Shimizu M, Hamano S, Nara T, Eto Y, Maekawa K : MRI findings of anterior spinal artery syndrome in childhood. *No To Hattatsu* **28** : 438-442, 1996. (Japanese)
- 20) Nagasaka S, Nara T, Shimizu M, Hamano S : Anterior spinal artery syndrome : Revealed by magnetic resonance imaging. *Journal of Saitama Children's Medical Center* **11** : 21-25, 1994. (Japanese)