

Case Report

## A Case of Schizencephaly Type I Associated with West Syndrome that Responded to ACTH Treatment

George Imataka<sup>1)</sup>, Shigeko Kuwashima<sup>2)</sup>, Teisuke Hashimoto<sup>2)</sup>,  
Hideo Yamanouchi<sup>1)</sup> and Osamu Arisaka<sup>1)</sup>

<sup>1)</sup> Department of Pediatrics, Dokkyo Medical University Tochigi, Japan

<sup>2)</sup> Department of Radiology, Dokkyo Medical University Tochigi, Japan

### SUMMARY

Although schizencephaly is known to be complicated by various types of epilepsy, complication by West syndrome is rare. We encountered a boy with West syndrome accompanied by schizencephaly. There was no abnormality in the birth history. After birth, the right upper and lower limb movements were less frequent and weaker than those on the left side. The neck was stabilized at 4 months of age. At 5 months of age, the boy developed infantile spasms, and hypsarrythmia was noted on EEG. Brain MRI detected schizencephaly fused with the cerebral wall in the left temporal to parietal region, and schizencephaly type I was diagnosed. From the clinical features of the seizures and EEG findings, he was diagnosed with symptomatic West syndrome. ACTH therapy was performed at 0.02 mg/kg day, and hypsarrythmia was improved on EEG on day 21 and the seizures disappeared. Seizures have been controlled to left facial partial seizures by anticonvulsive monotherapy with carbamazepine thereafter. Brain MRI after ACTH therapy detected cerebral cortical atrophy. On <sup>99m</sup>Tc ECD-SPECT performed at 7 months, a decreased cerebral blood flow and defect were noted in a consistent shape with the schizencephaly on the left side. Spastic paralysis of the right upper and lower limbs remains. The right ankle joint shows foot-drop, but the patient can walk with an orthosis attachment. The patient was enrolled in a general class in primary school, and mental retardation is mild. In the Discussion, the characteristics of epilepsy in schizencephaly and symptomatic West syndrome, and the cause of schizencephaly are described with a review of the literature.

**Key Words :** West syndrome, schizencephaly, ACTH, infantile spasm, magnetic resonance imaging

### INTRODUCTION

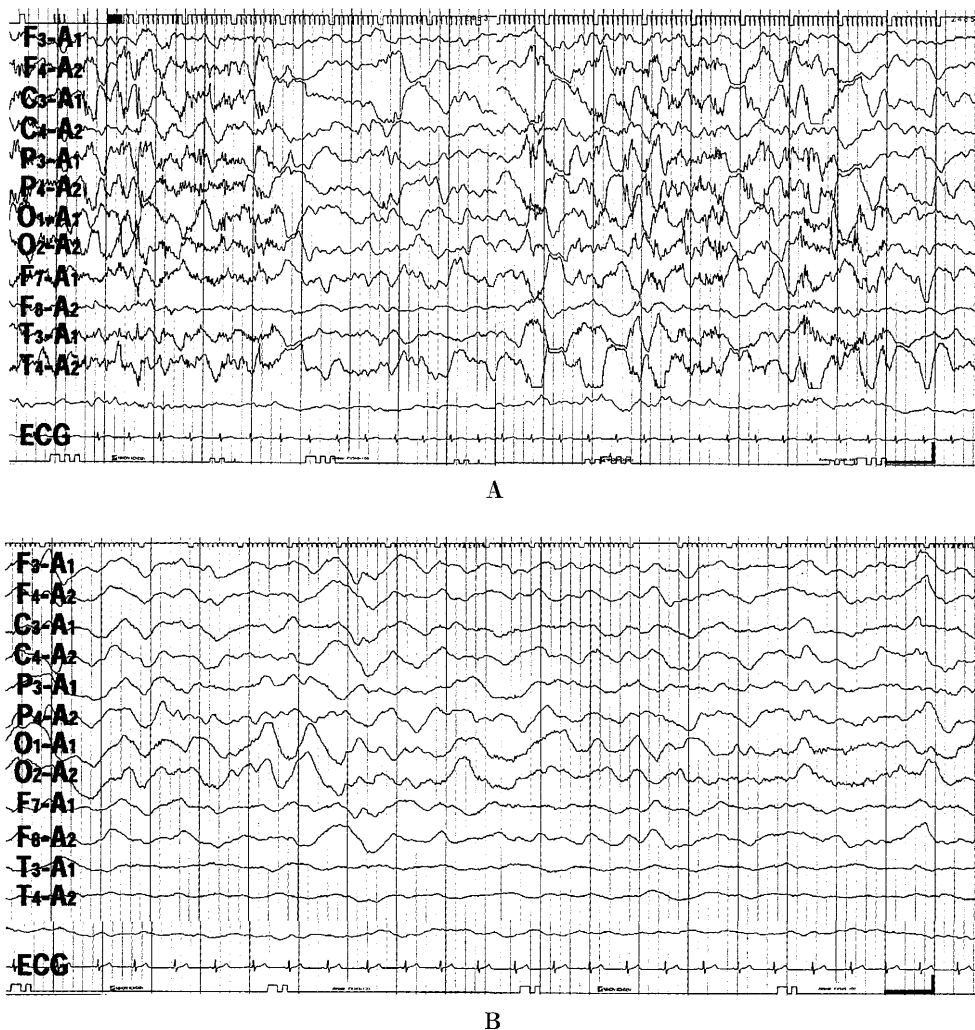
In 1946, Yakovlev and Wadsworth investigated autopsied patients with a cleft in the cerebral hemisphere, and defined schizencephaly<sup>1,2)</sup>. The morphological feature is the presence of symmetric clefts near the central sulcus. Since the lesion is thick and histo-

logically consists of gray matter rich in neurons, it is a congenital encephalodysplasia caused by impaired neuronal migration at about 6–7 months of embryonic age. Schizencephaly in which the cerebral wall composing the cleft is fused is classified as type I, and the cerebral walls are widely separated and complicated by hydrocephalus as type II. Clinically, severe retardation of psychomotor development, hemiplegia, quadriplegia, and intractable epilepsy accompany in many cases, but the incidence has been considered rare. However, cases with mild mental retardation and paralysis have been reported as MRI has become widely used<sup>3~5)</sup>. We encountered a male infant with unilateral

Received November 9, 2006 ; accepted January 10, 2007

Reprint requests to : George Imataka MD, PhD

Department of Pediatrics, Dokkyo Medical University, Mibu, Tochigi 321-0293, Japan  
e-mail : geo@dokkyomed.ac.jp



**Fig. 1**

**IA :** Multifocal spikes and slightly incomplete asymmetric hypsarrhythmia were noted on electroencephalogram in sleep non-seizure states. Considering the age of 5 months, West syndrome was diagnosed.

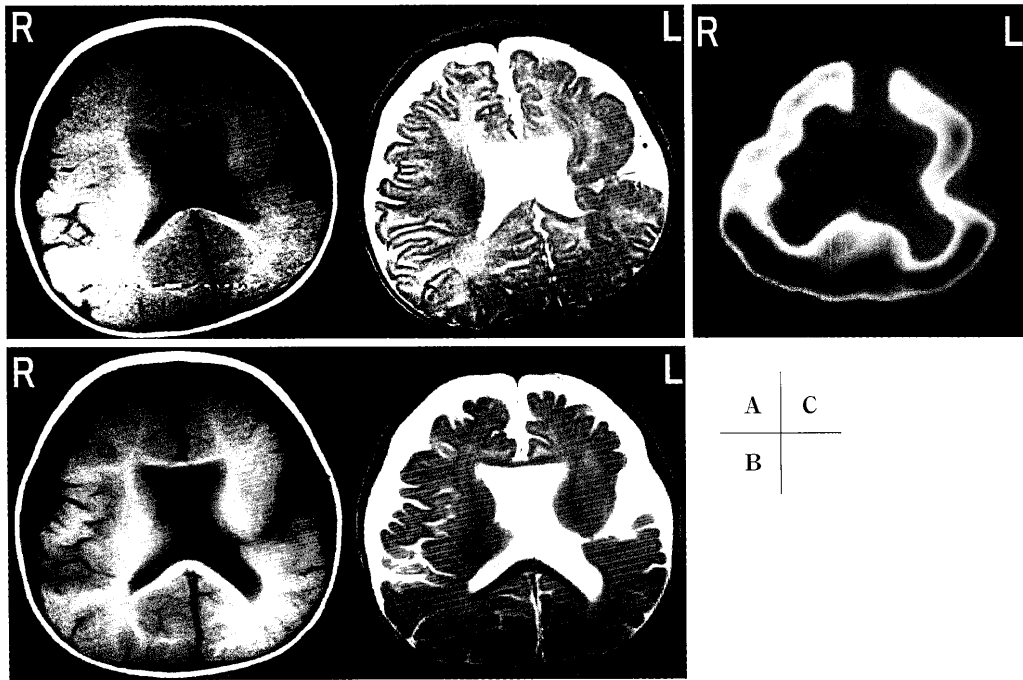
**IB :** Electroencephalograms in sleep non-seizure states on day 21 after the initiation of ACTH treatment are presented. Delta waves were dominant in the background activity, and fast waves were lost. No hypsarrhythmia or other epileptic spikes were noted.

motor disturbance with concomitant West syndrome. Brain MRI was performed, and left schizencephaly type I was diagnosed. Schizencephaly is known to be complicated by various types of epilepsy<sup>6,7)</sup>. However, complication by symptomatic West syndrome is rare. We report the clinical course of this patient with a discussion of the literature.

### CASE REPORT

The patient was a 5-month-old boy brought to our hospital for a chief complaint of repeated clustered tonic neck and salaam attacks, one of the types of infantile spasms. His father and mother were aged 42

and 27 years, respectively. Their first child was a 2-year-old girl, and her development was normal. The mother had no infection or medication during pregnancy. Intrauterine fetal development had been normal. The patient was born as the 2nd child at 38 weeks and 3 days of gestation by natural delivery, with a birth weight of 2640 g. No sign of asphyxia was noted. The movement and strength of the right upper and lower limbs were less than those of the left side, and the course was followed. Moro reflex was noted on both sides. The neck stabilized at 3.5 months of age. Since an attack of flexions of the bilateral upper limbs every 4–5 seconds for about 5 minutes in the supine position



**Fig. 2**

**2A** : Signals of cerebrospinal fluid continuing from the brain surface to ventricle were noted in the left temporal region. This region was surrounded by heterotopic gray matter, and thus, diagnosed as closed lip-type schizencephaly type I. The corpus callosum was imaged, but generally thinned. The cavity of the septum pellucidum was absent.

**2B** : An image after ACTH treatment is shown. An adverse effect of ACTH treatment, mild atrophy of the cerebral cortex, was noted, although it was also possible that the atrophy was associated with epilepsy.

**2C** : On  $^{99m}\text{Tc}$  ECD-SPECT performed about 2 months after ACTH treatment, a decreased cerebral blood flow and partial defect were noted in the region corresponding to the cleft region. Mild decreases in the blood flow were also noted in the bilateral frontal lobes, which may have reflected ACTH-induced cerebral atrophy.

repeatedly appeared 4 or 5 times a day at 5 months of age, the patient was brought to the outpatient clinic. The attacks were clinically diagnosed as infantile spasms consistent with West syndrome. Pursuit eye movement and smiling in response to bouncing were noted, and the boy recognized his mother, showing no apparent mental retardation. Muscular tension was slightly increased in the right upper and lower limbs. Regarding the deep tendon reflex of the extremities, the right side was increased dominantly in the biceps, triceps, and brachioradialis reflexes of the upper limbs. The knee and Achilles tendon reflexes were 3+ on the right side, showing strong positivity, and positive on the left side. The right ankle joint showed foot-drop. Multifocal spikes and hypsarrythmia were noted on electroencephalogram (EEG) in sleep non-seizure states (Fig. 1A). On brain MRI, abnormal signals were detected near the central sulcus extending from the left temporal to parietal regions, and schizencephaly

type I (closed-lip type) was diagnosed (Fig. 2A). A once daily intramuscular injection of ACTH at 0.02 mg/kg was initiated, and the frequency of seizures was decreased after the 9th hospital day. On EEG on the 21st day, the background activity was slowed, and spikes disappeared (Fig. 1B). Since brain MRI performed on the same day detected cerebral cortical atrophy (Fig. 2B), ACTH treatment was discontinued. Seizures were controlled by 10 mg/kg/day carbamazepine.  $^{99m}\text{Tc}$  ECD-SPECT was performed at 7 months of age, and a decreased cerebral blood flow and partial defect were noted in the schizencephaly region. Mild decreases in the blood flow were also noted in the bilateral frontal lobes (Fig. 2C).

The boy is now 7 years old. Epileptic facial partial seizures occur several times a year, but no grand mal has occurred, and anticonvulsive carbamazepine administration is being continued. The right side is dominant in deep tendon reflexes of the extremities. The

right ankle joint shows foot-drop, but the patient can walk with an orthosis attachment. The patient is enrolled in a general class in primary school and shows mild mental retardation.

## DISCUSSION

Schizencephaly in this patient was type I (closed-lip type) in which the cerebral wall of the cleft was fused on MRI. Schizencephaly is encephalodysplasia caused by impaired neuronal migration at about 7 months of embryonic age, and it is reported to be complicated by various types of epileptic seizures. As seizure types, simple partial seizure, complex partial seizure, secondary generalized seizure, febrile convulsion, generalized tonic-clonic seizure, myoclonic partial seizure, and infantile spasm have been reported<sup>8)</sup>. The incidence of seizure in schizencephaly is high, and it occurred in more than half of cases in many reports<sup>6,7)</sup>. However, West syndrome is frequently complicated by encephalodysplasia, and there have been many reports of lissencephaly, porencephaly, arachnoid cysts, hemimegalencephaly, tuberous cerebrosclerosis, neurofibromatosis, ectopic gray matter, focal cortical dysplasia, subcortical band heterotopia, and Aicardi syndrome, but fewer cases of schizencephaly have been reported<sup>8)</sup>. Delphine *et al.*<sup>8)</sup> investigated 30 cases of infantile schizencephaly, and found one case of infantile spasm. The course of epilepsy in schizencephaly was intractable in many cases, but schizencephaly with mild epilepsy has been occasionally reported as MRI has become widely used. The course of West syndrome in this patient has been good because the patient is independent in daily life.

However, epilepsy developing after 10 years of age in many cases in which neurological symptoms were mild during infancy has been reported as a characteristic of epilepsy in schizencephaly<sup>6)</sup>. The reason for the advanced onset age in many cases, despite epilepsy being associated with malformation, is unclear. Cases that developed intractable epilepsy after 10 years of age and required surgical treatment have been reported<sup>9~12)</sup>. The epileptogenicity in schizencephaly varies among cases, but the presence of an epileptogenic focus in ectopic gray matter covering the cleft has been reported. As the elucidation of epileptogenic foci progresses with the advancement of neuroradiological imaging diagnosis, application of epileptic surgery to schizencephaly

cases may increase. The prognosis is good in some cases, as in this patient so far, and its developmental mechanism has been investigated. Regarding the pathogenesis, schizencephaly-complicating environmental factors, such as impaired placental blood flow in the early embryonic period, placental cytomegalovirus infection, and familial intracranial arteriovenous malformation, have been reported<sup>4~13)</sup>. Regarding the genetic mechanism, Brunelli *et al.*<sup>14)</sup> identified heterozygous mutation in the homeobox gene, *EMX2*, in 7 sporadic cases by gene analysis of familial schizencephaly with autosomal dominant inheritance in 1996. In this patient, there was no apparent cause in the mother, and identification of the cause was not possible. As discussed above, intractable epilepsy developed after 10 years of age in many cases. Thus, the patient will be carefully followed.

*Acknowledgements.* This work was supported by the Dokkyo Medical University, Investigator-Initiated Research Grant (No. 2005-01-5) and the Ministry of Education, Culture, Sports, Science and Technology (MEXT) KAKENHI 18790733 Grant-in-Aid for Young Scientists (B).

## REFERENCES

- 1) Yakovlev PI, Wadsworth RC. Schizencephalies : A study of the congenital clefts in the cerebral mantle : 1. Clefts with fused lips. *J Neuropathol Exp Neurol*, **5** : 116-130, 1946.
- 2) Yakovlev PI, Wadsworth RC. Schizencephalies : A study of the congenital clefts in the cerebral mantle : 2. Clefts with hydrocephalus and lip separated. *J Neuropathol Exp Neurol*, **5** : 169-206, 1946.
- 3) Aniskiewicz AS, Frumkin NL, Brady DE, Moore JB, Pera A. : Magnetic resonance imaging and neurobehavioral correlates in schizencephaly. *Arch Neurol*, **47** : 911-916, 1990.
- 4) Barkovich AJ, Norman D. : MR imaging of schizencephaly. *AJNR Am J Neuroradiol*, **9** : 297-302, 1988.
- 5) Barkovich AJ, Kjos BO. Schizencephaly : Correlation of clinical findings with MR characteristics. *AJNR Am J Neuroradiol*, **13** : 85-94, 1992.
- 6) Granata T, Battaglia G, D'Incerti L, Franceschetti S, Spreafico R, Battino D, Savoiaro M, Avanzini G. Schizencephaly : Neuroradiologic and epileptologic

- findings. *Epilepsia*, **37** : 1185-1193, 1996.
- 7) Packard AM, Miller VS, Delgado MR. Schizencephaly : Correlations of clinical and radiologic features. *Neurology*, **48** : 1427-1434, 1997.
- 8) Delphine D, Jean-Francois C, Murel B et al. Schizencephaly : clinical and imaging features in 30 infantile cases. *Brain Dev*, **22** : 475-483, 2000.
- 9) Landy HJ, Ramsay RE, Ajmone-Marsan C, Levin BE, Brown J, Pasarin G, Quencer RM. : Temporal lobectomy for seizures associated with unilateral schizencephaly. *Surg Neurol*, **37** : 477-481, 1992.
- 10) Leblanc R, Tampieri D, Robitaille Y, Feindel W, Andermann F. : Surgical treatment of intractable epilepsy associated with schizencephaly. *Neurosurgery*, **29** : 421-429, 1991.
- 11) Maehara T, Shimizu H, Nakayama H, Oda M, Arai N. : Surgical treatment of epilepsy from schizencephaly with fused lips. *Surg Neurol*, **48** : 507-510, 1997.
- 12) Silbergeld DL, Miller JW. : Resective surgery for medically intractable epilepsy associated with schizencephaly. *J Neurosurg*, **80** : 820-825, 1994.
- 13) Imataka G, Hashimoto T, Yamanouchi H, Eguchi M. : Schizencephaly type I : Magnetic resonance imaging and single photon emission computed tomography features. *Dokkyo J Med Sci*, **31** : 159-160, 2004.
- 14) Brunelli S, Faiella A, Capra V et al : Germline mutations in the homeobox gene *EMX2* in patients with severe schizencephaly. *Nat Genet*, **12** : 94-96, 1996.